

Normolipemic Mucocutaneous Eruptive Xanthoma

To the Editor. - An 18-year-old female presented at our polyclinic with complaints of widespread yellow-brown skin lesions. This had started 6 years earlier on her arm and within a short time had spread over her whole body in the form of slightly itchy yellowish blisters. For last one year she developed similar lesions inside her mouth, in the genital area and in her eyes. There was no similar family history. Dermatological examination showed generalised distribution of yellow-brown papules and plaques over the skin [Figure 1]. There were many coloured mucosal papules in the nasopharynx with hypopharynx, oropharynx and buccal mucosal surfaces [Figure 2].

In the right eye, there was a yellow plaque on the bulbar conjunctiva near the limbus or was it a yellowish ring surrounding the limbus. In the laboratory evaluation, the results of blood cells, hemogram, blood sugar, liver and kidney function tests, blood lipid profile values, serum protein and lipid electrophoresis, HBs antigen, anti-HBs Ab, anti-HBc Ab, anti HIV Ab and complete urine analysis were all normal. The ECG and ECHO were normal. There was nothing remarkable in the abdominal USG, CT and brain MRI examinations. The histopathology examination results were consistent with eruptive xanthoma [Figure 3].

Eruptive xanthomatosis is a skin disease in which yellowish red papules are seen on the outer surface of the arms and legs. Eruptive xanthomas are related to hypertriglyceridemia and chylomicronemia which occur associated with genetic disorders (primary hyperlipoproteinemia) or an underlying disease (secondary hyperlipoproteinemia) such as diabetes mellitus, hypothyroidism, nephrotic syndrome, pancreatitis or retinoid or estrogen therapy [1]. Normolipemic eruptive xanthomas have rarely been reported [2, 3]. In our case, the lipid profile, laboratory and radiological tests were normal.

In cases of severe hypertriglyceridemia, lipids can accumulate in the skin (eruptive xanthomas) and the retina. In eruptive xanthomas disease, ophthalmic findings have been reported such as xanthelasmata, corneal arcus and lipemia retinalis [4, 5, 6, 7, 8]. In literature, lesions in the pharynx have been reported in only 1 case with normolipidemic xanthoma disseminatum [9]. In our case, the diagnosis was different and there was no epipharynx involvement. However, there were many eruptive xanthoma lesions in the buccal mucosa,

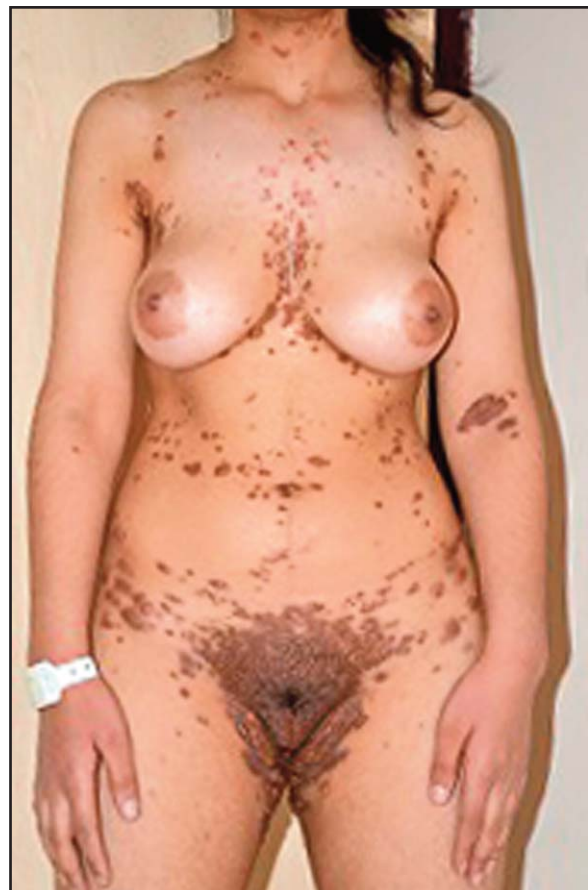

Figure 1. There was generalised distribution of yellow-brown papules and plaque over the skin

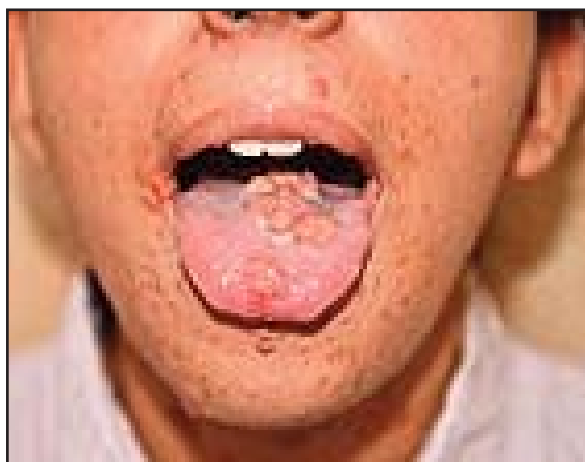


Figure 2. There were yellowish coloured papules on the tongue

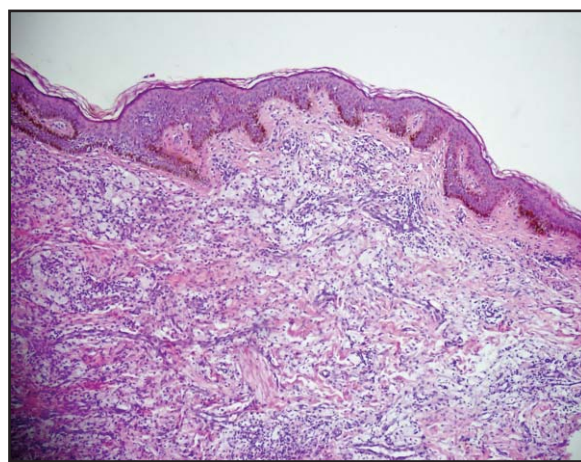


Figure 3. The histopathology examination were compatible with the view eruptive xanthoma

oropharynx, hypopharynx and nasopharynx. To the best of our knowledge, this has not previously been reported in literature together with eruptive xanthoma lesions in the ear helix, as in our case.

In conclusion, our case has different characteristics from other reported cases of eruptive xanthomas with eye involvement and eruptive xanthoma lesions were seen in the ear helix, buccal mucosa, oropharynx, hypopharynx and nasopharynx despite the normal levels of the lipid profile.

Hacer Altun Sürücü,¹ MD
Yavuz Yeşilova,¹ MD
Enver Turan,¹ MD
Ali Akal,² MD
Mustafa Aksoy,¹ MD

¹Harran University School of Medicine, Department of Dermatology, Sanliurfa, Turkey,

²Harran University School of Medicine, Department of Eye, Sanliurfa, Turkey

E-mail: yavuzyesilovagmail.com

References

1. Pickens S, Farber G, Mosadegh M. Eruptive xanthoma: a case report. *Cutis* 2012; 89: 141-144.
2. Huang HY, Liang CW, Hu SL, Cheng CC. Normolipemic papulo eruptive xanthomatosis in a child. *Pediatr Dermatol* 2009; 26: 360.
3. Caputo R, Monti M, Berti E, Gasparini G. Normolipemic eruptive cutaneous xanthomatosis. *Arch Dermatol* 1986; 122: 1294-1297.
4. Henning JS, Fazio MG. Yellowish papules on a middle-aged man. *Eruptive xanthoma*. *Am Fam Physician* 2011; 83: 73-74.
5. Zabeen B, Khaled Z, Nahar J, Baki A, Amin F, Akhter S, Begum T, Azad K, Nahar N. Hypertriglyceridemia associated with eruptive xanthomas and lipemia retinalis in newly diagnosed diabetes mellitus. *Mymensingh Med J* 2013; 22: 591-595.
6. Winder AF, Dodson PM, Galton DJ. Ophthalmological complications of the hypertriglyceridemias. *Trans Ophthalmol Soc U K* 1980; 100: 119-122.
7. Segal P, Insull W Jr, Chambless LE, Stinnett S, La-Rosa JC, Weissfeld L, Halfon S, Kwiterovitch PO Jr, Little JA. The association of dyslipoproteinemia with corneal arcus and xanthelasma. The Lipid Research Clinics Program Prevalence Study. *Circulation* 1986; 73: 1108-1118.
8. Alexander LJ. Ocular signs and symptoms of altered blood lipids. *J Am Optom Assoc* 1983; 54: 123-126.
9. Weiss N, Keller C. Xanthoma disseminatum: a rare normolipemic xanthomatosis. *Clin Investig* 1993; 71: 233-238.