



ELSEVIER

European Journal of Cardio-thoracic Surgery 22 (2002) 649–650

EUROPEAN JOURNAL OF
CARDIO-THORACIC
SURGERY

www.elsevier.com/locate/ejcts

Case report

Complications of albendazole treatment in hydatid disease of lung

Ibrahim Can Kurkcuoglu^{a,*}, Atilla Eroglu^a, Nurettin Karaoglanoglu^a, Pinar Polat^b

^aDepartment of Thoracic Surgery, School of Medicine, Ataturk University, 25240 Erzurum, Turkey

^bDepartment of Radiology, School of Medicine, Ataturk University, 25240 Erzurum, Turkey

Received 17 April 2002; received in revised form 7 June 2002; accepted 19 June 2002

Abstract

We present rupture of lung hydatid cyst in a patient with multiple organ involvement during albendazole treatment. The patient was first provided mechanical ventilation than residue cavity and the other intact cyst was treated surgically. We concluded that albendazole should be used in postoperative period in patients with hydatid disease of the lung to prevent recurrent disease. © 2002 Elsevier Science B.V. All rights reserved.

Keywords: Hydatid disease; Treatment; Complication; Lungs

1. Introduction

Mebendazole and albendazole have been used in the treatment of hydatid disease since 1980s. The changes caused by the drug in the permeability, morphology, and size of the lesions suggest that mebendazole attacks the parasites' germinal layer, which plays a major role in homeostasis and regulation of its metabolic exchanges with its external environment [1]. Albendazole and its metabolites, which reach high concentrations in the serum and hydatid fluid cause the death of cyst [2]. Rupture of the lung hydatid cysts may lead to severe complications.

2. Case report

A 32-year-old woman was admitted to the Department of Cardiovascular Surgery with complaints of bilateral feet pain and loss of pulse. The patient was operated upon urgently at that clinic; and bilateral femoral embolectomy was performed. The embolectomy material was in gray-white color and $2.5 \times 1.5 \times 0.5$ mm in size. Histopathological examination revealed cuticular membrane in lamellose eosinophilic structure. The systemic examination showed cardiac, pulmonary (Fig. 1) and cranial hydatid cyst. The patient received albendazole (10 mg/kg/day). On the eighth day of the treatment, the patient was admitted to the Department of Thoracic Surgery with the complaints of dyspnea,

fever and rashes. On the physical examination, the breath rate was found to be 37/min, blood pressure was 90/60 mmHg, pulse 100/min, PaO₂ 58 mmHg and PCO₂ 50 mmHg. Follow-up-computed tomography sections showed perforation, and complete drainage of one of the cyst of lung (Fig. 2). Intubation and mechanical ventilation were applied to the patient and albendazole treatment was stopped. As the patient responded to the mechanical ventilation and supported treatment, the respiratory support was stopped on the second day. Cystotomy, partial pericystectomy and capitonnage were performed on the two cysts at the right lower lobe via posterolaterale thoracotomy on the fifth day of perforation. The patient received albendazole in postoperative period.

3. Discussion

The compounds of benzimidazole decrease glycogen by affecting the glucose absorption mechanism at the membrane of hydatid cyst. Degenerative changes that occur at the endoplasmic reticulum and mitochondria of germinal cells and the increase in the number and the activity of the lysosomes cause cellular autolysis [3]. In vivo human studies have shown the presence of albendazole sulphoxide (principal metabolite of albendazole) in the cyst fluid, and have shown higher concentrations in patients treated for more than 24 h [4]. Between third and fourteenth days of the treatment of the lung hydatid cysts, the germinal layer may be intact or partially damaged [2]. There have been some studies in the literature that reported the rupture

* Corresponding author. Tel.: +90-442-3166-333; fax: +90-442-3166-340.

E-mail address: cankurkcuoglu@hotmail.com (I.C. Kurkcuoglu).

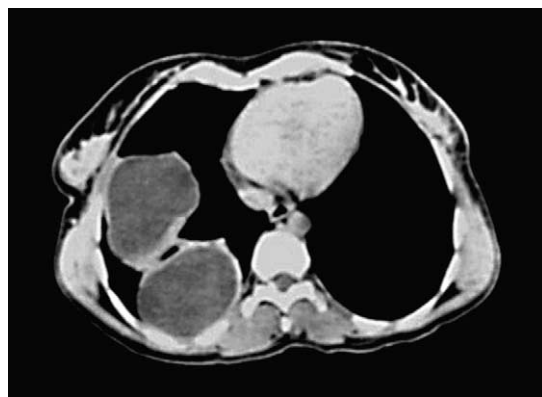


Fig. 1. Axial CT section in narrow window width shows hypodense cystic lesions with regular contours and surrounded by normal lung tissue.

of the cyst hydatid during and after the cessation of albendazole treatment [5]. Cyst can maintain its viability despite the high concentration of albendazole in the serum and cyst fluid, and also protoscoles that maintain their viability in death cyst [2,4,6]. Rupture of the hydatid cyst into an adjacent bronchus may be manifested by vigorous coughing and expectoration of a large amount of salty sputum consisting of mucus, hydatid fluid, and, occasionally, fragment of the laminated membrane. The patient may develop a severe hypersensitivity reaction manifested by generalized rash, high fever, pulmonary congestion, and severe bronchospasm. Occasionally, the intrabronchial rupture of the cyst manifests with sudden and severe dyspnea, which may lead to suffocation and death from complete tracheal obstruction by fragments from the hydatid membrane [7].

Clinical course differs according to cyst hydatid localization at the liver or lung. Albendazole is widely used as a primary treatment in hydatid disease of the liver and successful results have been reported [8]. However, it is mostly expected to result in suppuration that leads to the formation of an abscess in the rupture of lung hydatid cyst. Chemotherapy alone is not reliable in controlling lung hydatid disease. Even if the parasite in the lung dies, the membranes retained in the lung become the source of recurrent infections [9].

We are of the view that surgical treatment of the lung cyst should be preferred firstly in cases of lung hydatid cyst disease with the involvement of multiple organs. The application of medical treatment in inoperable cases and in cases that do not accept surgical treatment should be considered as a process with high risks. Rupture of cyst should be considered as inevitable during the medical therapy and the patient should be hospitalized. Following rupture, the need for mechanical ventilation, anaphylaxis and hypersensitivity reactions should be evaluated immediately.

In conclusion, we suggest that in patients with hydatid disease of the lungs associated with multiple organ involve-

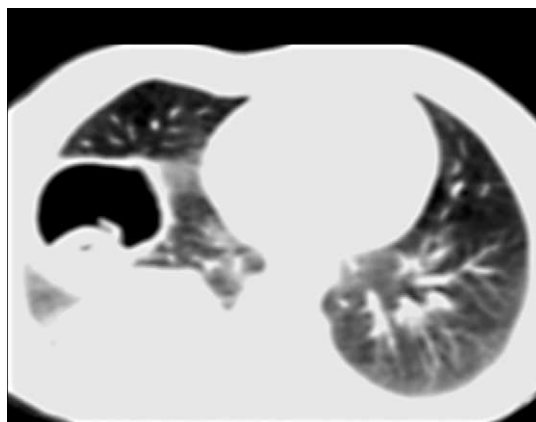


Fig. 2. Axial CT section taken 8 days after the first examination, and the same level shows rupture of the anteriorly located lesion. The cystic cavity is presently filled with air and germinative membrane is seen in the dependent portion of the lesion. The other cystic cavity is still intact and fills with cystic fluid.

ment, medical treatment should not be given before the removal of hydatid cyst of lung. Primarily, applied medical therapy may cause rupture of the lung cyst, and respiratory problems. We thought that medical treatment should be given after surgical therapy, after the hospitalization of the patient.

References

- [1] Bekhti A, Schaaps JP, Capron M, Dessaint J-P, Santoro F, Capron A. Treatment of hepatic hydatid disease with mebendazole: preliminary results in four cases. *Br Med J* 1977;2:1047–1051.
- [2] Saimot AG, Meulemans A, Cremieux AC, Giovanangeli MD, Hay JM, Delaitre B, Coulaud JP. Albendazole as a potential treatment for human hydatidosis. *Lancet* 1983;17:652–656.
- [3] Khuroo MS, Dar MY, Yattoo GN, Showkat AZ, Javaid G, Khan BA, Boda MI. Percutaneous drainage versus albendazole therapy in hepatic hydatidosis: a prospective, randomized study. *Gastroenterology* 1993;104:1452–1459.
- [4] Morris DL, Chinnery JB, Georgiou G, Stamatakis G, Golematas B. Penetration of albendazole sulphoxide into hydatid cysts. *Gut* 1987;28:75–80.
- [5] Morris DL, Dykes PW, Dickson B, Marriner SE, Bogan JA, Burrows FGO. Albendazole in hydatid disease. *Br Med J* 1983;286:103–104.
- [6] Morris DL, Dykes PW, Marriner SE, Bogan J, Burrows F, Skeene-Smith H, Clarkson MJ. Albendazole – objective evidence of response in human hydatid disease. *J Am Med Assoc* 1985;253:2053–2057.
- [7] Aletras H, Symbas PN. Hydatid disease of the lung. In: Shields TW, LoCicero III J, Ponn RB, Ponn RB, editors. *General thoracic surgery*. Philadelphia, PA: Lippincott Williams & Wilkins, 2000. pp. 1113–1122.
- [8] Balik AA, Basoglu M, Celebi F, Oren D, Polat KY, Atamanalp SS, Akcay MN. Surgical treatment of hydatid disease of the liver: review of 304 cases. *Arch Surg* 1999;134:166–169.
- [9] Peleg H, Best L, Gainiti D. Simultaneous operation for hydatid cysts of right lung and liver. *J Thorac Cardiovasc Surg* 1985;90:783–787.