

Giant Neurofibroma of the Chest Wall

Nurettin Karaođlanođlu, MD, Ibrahim Can K rk ođlu, MD, and Atilla Erođlu, MD

Atat rk University, Medical Faculty, Department of Thoracic Surgery, Erzurum, Turkey

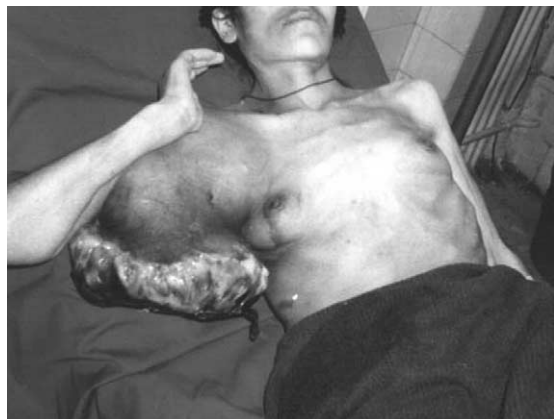

Fig 1.




Fig 3.

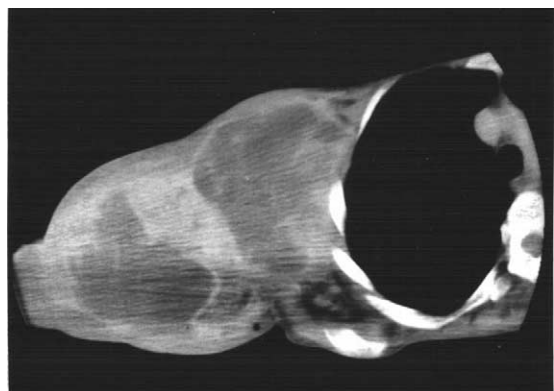


Fig 2.

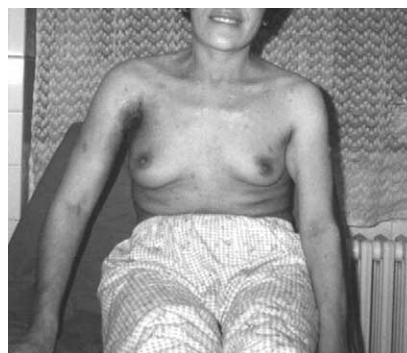

Fig 4.

A 20-year-old female was admitted with a slow-growing, painless, giant mass originating from the right axillary and thorax wall. On physical examination, the mass was hard, fixed, necrotized, and nontender (Fig 1). Magnetic resonance imaging and Computed tomography of the chest (Fig 2) confirmed a well-defined heterogeneous soft tissue density tumor without signs of rib erosion or axillary vascular connection. An incisional

biopsy of the tumor established the diagnosis of neurofibroma (Fig 3). Resection of the entire soft tissue mass was performed. At surgery a well-circumscribed mass not attached to ribs and axillary vascular tissue was found. After resecting a $27 \times 19 \times 16$ cm mass, the chest wall and axillary cutaneous defect was reconstructed with musculocutaneous flap. She had an uneventful recovery and was discharged home 10 days after surgery. She is doing well at the 10-month follow-up visit (Fig 4).

It is impossible to surgically remove all neurofibromas, but resection of large and aggressive fibromas can improve a patient's condition and provide good quality of life.

Address reprint requests to Dr Dr Karaođlanođlu, Department of Thoracic Surgery, Faculty of Medicine, Atat rk University, 25240 Erzurum, Turkey; e-mail: nkaraoglanoglu@hotmail.com.